Skriptenreihe

Band Anatomie 3 / Abbildung 3

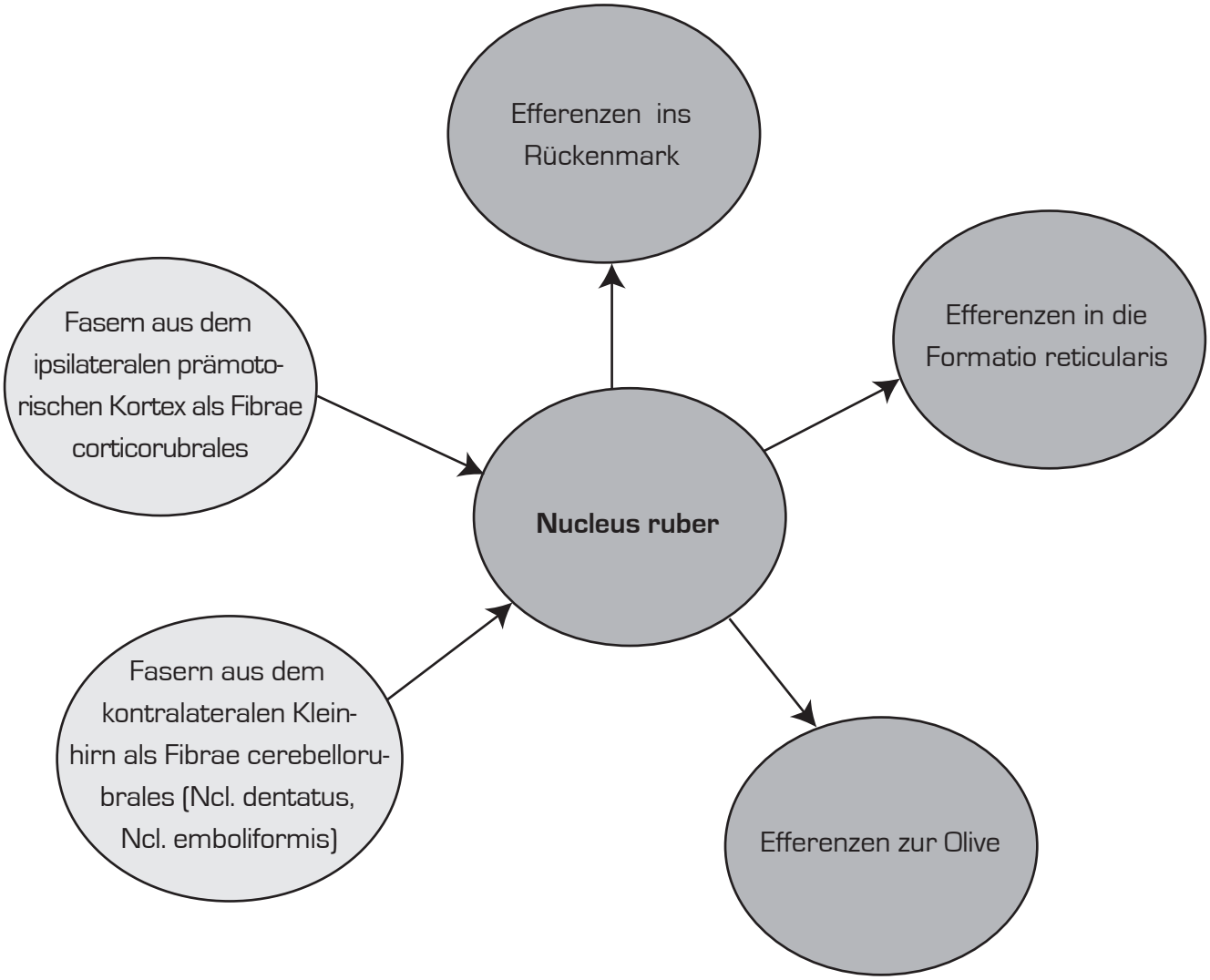

© MEDI-LEARN

Wichtige Projektionen des Ncl. ruber