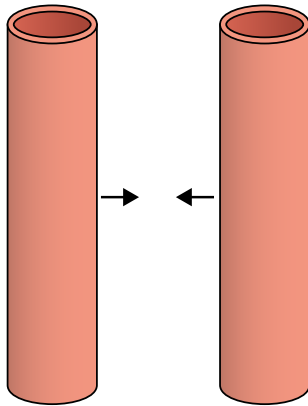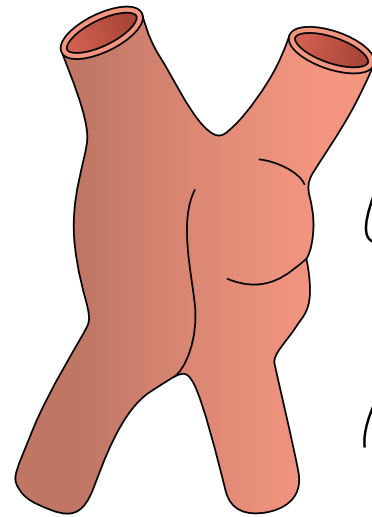

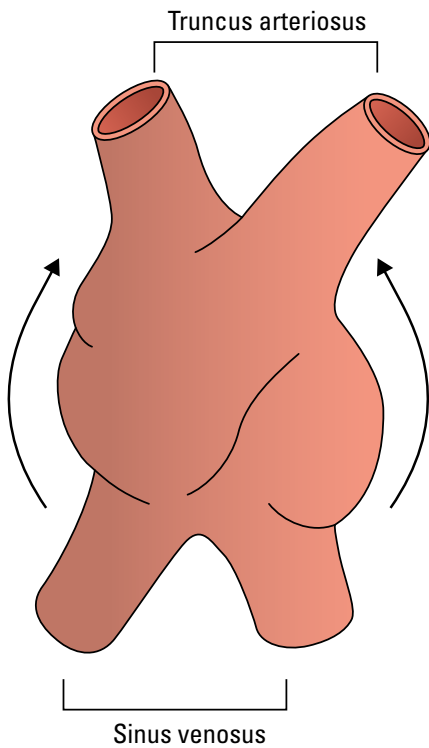



ventrale Aorten = Endothelschläuche

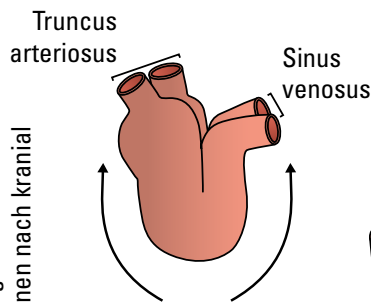


verschmolzene ventrale Aorten  
= Herzschauch  
(bereits Eigenfrequenz)



Herzschleife

Ansicht von lateral



Umlagerung der kaudalen  
Strohbahnen nach kranial



Ansicht von ventral

