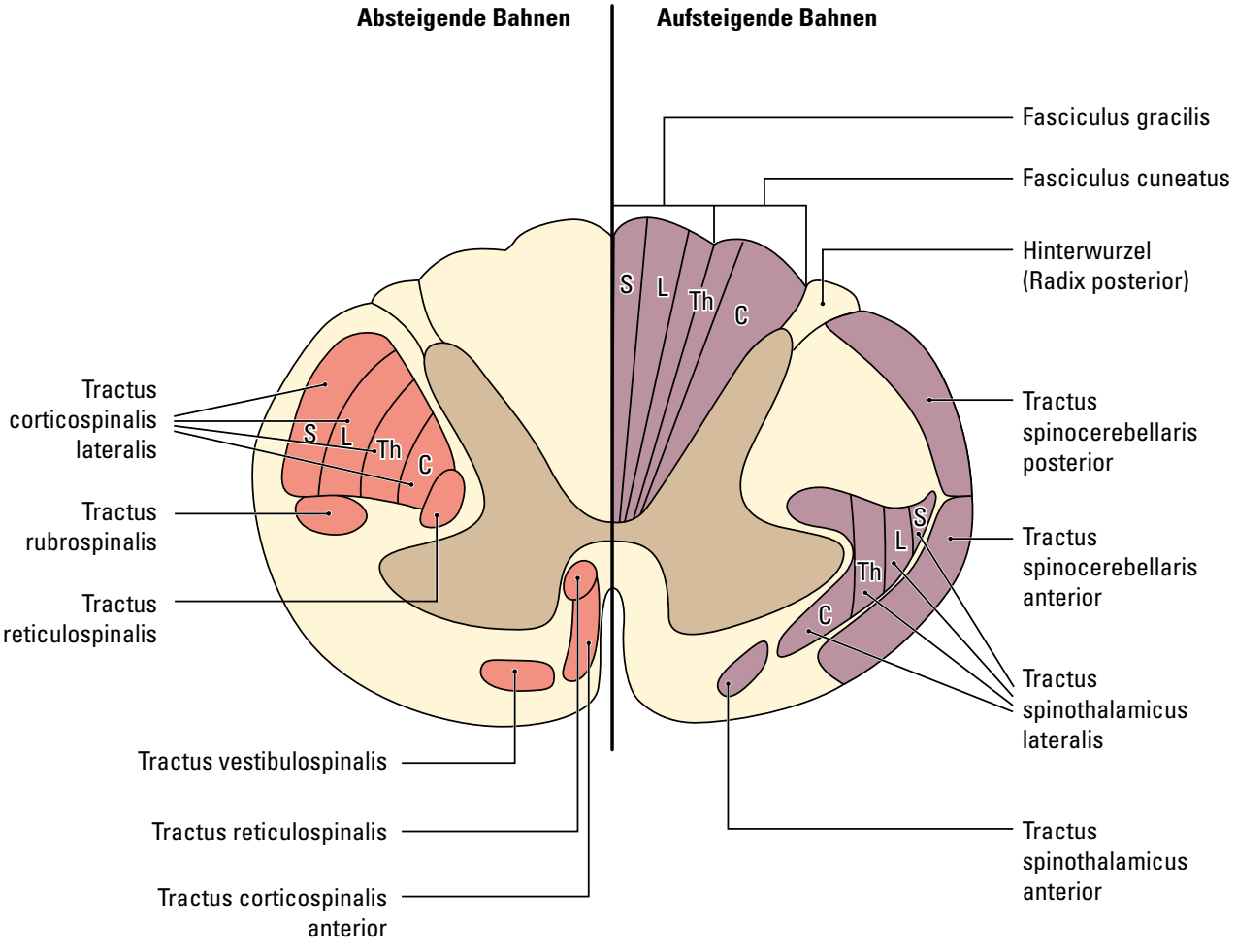

Somatotopik der Rückenmarksbahnen