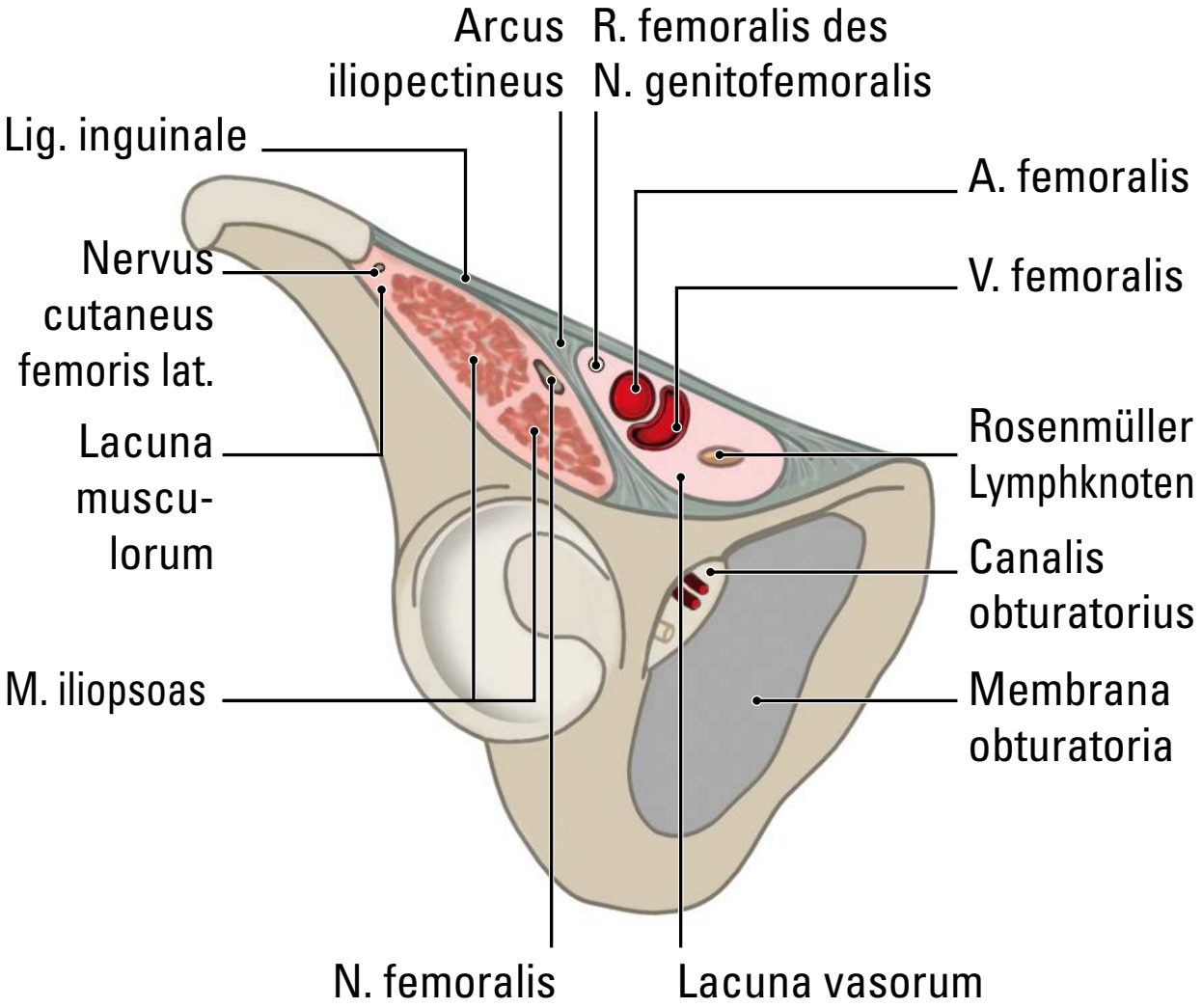
Arcus iliopectineus
R. femoralis des N. genitofemoralis
Lig. inguinale
A. femoralis
Nervus cutaneus femoris lat.
V. femoralis
Lacuna muscu-lorum
Rosenmüller Lymphknoten
Canalis obturatorius
M. iliopsoas
Membrana obturatoria
N. femoralis
Lacuna vasorum