Skriptenreihe

Band Anatomie 3 / Abbildung 20

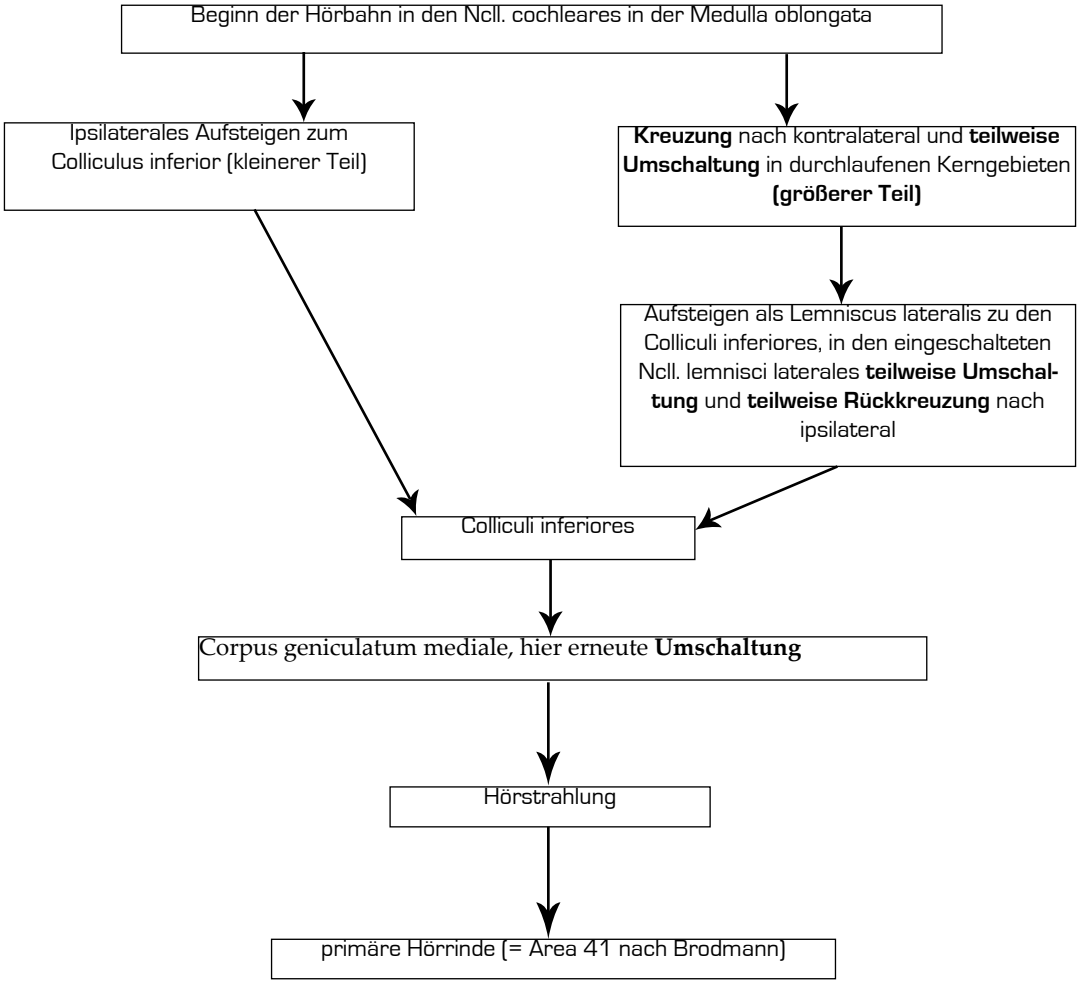

© MEDI-LEARN